

Epidermoid Cyst of the Sole - A Case Report

SATHYAKRISHNA BASAVAPATNA RAMAKRISHNAIAH¹, SANTOSH SINGH RAJPUT², NAYAR SAJEETH GOPINATHAN³

ABSTRACT

Epidermoid cysts are common benign subcutaneous lesion also termed as epidermal cysts. Epidermoid cyst are commonly seen in hairy regions of body like scalp, face and scrotum, can be single or multiple, but rarely can occur in glabrous skin of palm and sole. They are known to result from progressive cystic ectasia of the infundibular portion of hair follicle but the pathogenesis in palmo-plantar epidermoid cyst differs that is traumatic sequestration of epidermal elements into dermis. Here, we report a case of 30-year-old female presented with complaints of swelling in her left sole. On examination a palpable firm swelling was noted just below the 2nd web space left foot plantar region, on X-ray foot no osseous lesion or foreign body was detected. Swelling was excised and sent for histopathological examination which confirmed it as epidermoid cyst.

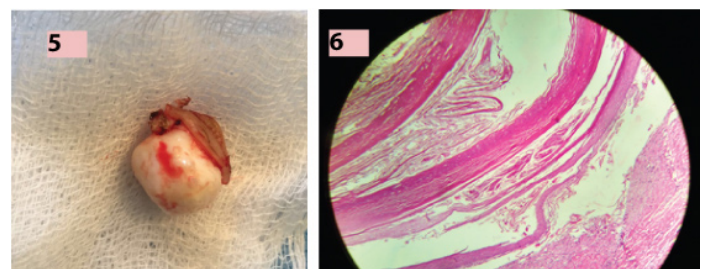
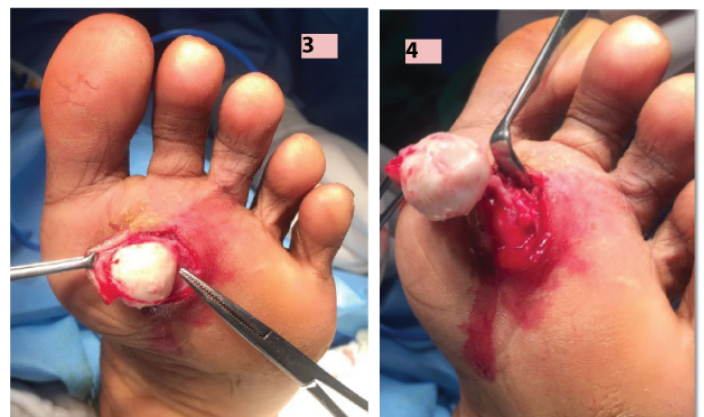
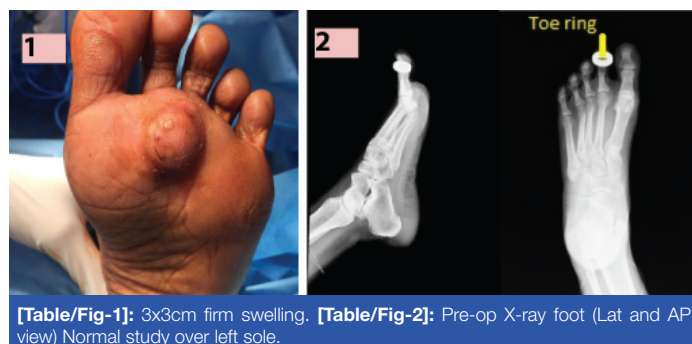Keywords: Palmoplantar cyst, Sequestration, Trauma

CASE REPORT

A 30-year-old healthy female presented to our outpatient department with complains of swelling in her left sole and discomfort during walking. Patient history was swelling of 6 months duration gradually increasing in size. According to the patient there was history of trauma with a sharp pointed object 6 months back. General physical examination was unremarkable. Local examination [Table/Fig-1] revealed a solitary 3x3cm firm soft tissue swelling located in the left foot under the head of 2nd and 3rd metatarsal. Swelling was in subcutaneous plane, mobile and overlying skin not pinchable. There were no signs of inflammation. Metatarsophalangeal joint movements were normal. Rest of the foot was normal.

Routine blood tests were normal. Radiographic examination [Table/Fig-2] of foot was normal. Fine Needle Aspiration Cytology (FNAC) was done to confirm the diagnosis. FNAC showed features of epidermoid cyst.

Informed consent was obtained and excision of the swelling was performed [Table/Fig-3,4] under spinal anaesthesia. Vertically oval skin incision was made over the swelling and swelling was excised in toto. Excised tissue was sent for histopathological examination. Intraoperative finding [Table/Fig-5] was 3x3 cm sized well encapsulated cystic lesion containing pultaceous material. Post-operative period was uneventful. Histopathology [Table/Fig-6] report showing a thin fibro-collagenous cyst wall lined by stratified squamous epithelium with prominent granular layer. Cyst contains lamellated keratin, which confirmed it as epidermoid cyst.



DISCUSSION

Common lesions on sole are corns, callus, plantar warts, foreign body reactions, etc. but epidermoid cyst can be a surgeons surprise on sole. Epidermoid cyst is a retention cyst in relation to sebaceous gland. It results from progressive cystic ectasia of the infundibular portion of hair follicle [1]. In palm and sole, as there are no sebaceous glands or hair follicles, so it was initially thought that epidermoid cyst does not occur in these regions, but as these cysts also presented in these regions hence different aetiopathogenesis was postulated that is:

1) Traumatic implantation of epidermal cells into the dermis or foreign body reaction [2-5]. Sometimes microtraumatic event like irritation can act as a precipitating factor [4]. Hence, traumatic sequestration is thought to be the etiology of epidermoid cyst on palm and sole;

2) Egawa et al., suggested that plantar epidermal cyst may develop from eccrine ducts due to Human Papilloma Virus (HPV) infection [6]. HPV may have a high affinity for eccrine duct epithelium, they infect the distal portion of the eccrine duct and then migrate into its dermal portion, finally leading to the formation of an epidermoid cyst.

On gross examination epidermoid cyst appears pearly white because of the shiny smooth waxy character of the keratin. On microscopic examination as epidermoid cyst lack the dermal appendages, squamous lining will be thin and desquamation of this epithelium results in debris which consists of keratin, and proteinaceous material [7]. An organism called *Demodex folliculorum* may be found in the wall of the cyst [8].

Ghani et al., reported a case of heel pain not responding to conservative treatment. MRI scan revealed a soft tissue mass, after surgical excision found to be an epidermal cyst [9]. After procedure patient was asymptomatic. In our case patient presented with swelling in the sole and discomfort during walking.

Ferguson et al., reported a case of epidermoid cyst formation following Topaz coblation for plantar fasciitis [10]. Our patient had not received any treatment before visiting to our OPD.

Shimizu Y et al., studied clinicopathological features of epidermal cyst of sole comparison with traditional epidermoid cyst in which microscopy showed presence of parakeratosis and focal lack of granular layer, but in our case predominantly granular layer seen with no parakeratosis [11].

The treatment consists of surgical excision of the whole lesion, including capsule of the cyst, to avoid recurrences. It is important to avoid damaging the cyst during excision to avoid the formation of a keratotic granuloma of giant cells. Harish et al., reported a case of keratin granuloma due to ruptured epidermal cyst in 52-year-old woman [12]. There was no epidermoid cyst rupture in our case.

Complications in the form of inflammation, infection and rupture with foul smelling discharge may occur in epidermoid cyst. Although epidermoid cysts are benign lesion malignant transformation into basal cell carcinoma and squamous cell carcinoma has been described in few cases [4,5].

CONCLUSION

Epidermoid cyst is a cystic benign lesion of rare occurrence in the sole. Usually asymptomatic except when they occur in high pressure areas. Epidermoid cyst may be surgeons on table surprise hence, epidermoid cyst should be in the list of differential diagnosis for the swelling of the sole. Treatment is simple surgical excision.

REFERENCES

- [1] Kirkham N. Tumours and cysts of epidermis. In: Elder DE, Elitsas R, Johnson jr BL, Murphy GF, editors. *Lever's histopathology of the skin*. 9th ed. Philadelphia: Lippincott Williams and Wilkins, 2005: 814-15.
- [2] Shimizu Y, Sakita K, Arai E, et al. Clinicopathologic features of epidermal cysts of the sole: comparison with traditional epidermal cysts and trichilemmal cysts. *J Cutan Pathol*. 2005;32(4):280-85.
- [3] Hall JP, Sheffey RJ, Chagares WE, et al. Epidermal inclusion cyst in the foot of a Vietnam veteran. *JAPMA*. 2006;96(5):445-47.
- [4] Coulter PD, Bouché RT. Traumatically induced inclusion cyst secondary to shoe impingement: report of three cases. *J Foot Ankle Surg*. 1999;38(4):271-77.
- [5] Sheff J, Bregman P, Curran T. Bilaterally symmetrical epidermal inclusion cysts with foreign-body giant-cell reaction. *JAPMA*. 1988;88(8):410-13.
- [6] Egawa K, Honda Y, Inaba Y, et al. Detection of human papillomaviruses and eccrine ducts in palmoplantar epidermoid cysts. *Br J Dermatol*. 1995;132(4):533-42.
- [7] Smirniotopoulos JG, Chiechi MV. Teratomas, dermoids and epidermoids of the head and neck. *Radiographics*. 1995;15(6):1437-55.
- [8] Baima B, Sticherling M. Demodicidosis revisited. *Acta Derm Venereol*. 2002;82(1):3-6.
- [9] Ghani S, Fazal MA. An unusual cause of intractable heel pain. *J Foot Ankle Surg*. 2011;50(6):744-46.
- [10] Ferguson K, Thomson AG, Moir JS. Case study: Epidermoid cyst following percutaneous Topaz coblation for plantar fasciitis. *Foot (Edinb)*. 2012;22(1):46-47.
- [11] Shimizu Y, Sakita K, Arai E, et al. Clinicopathological features of epidermal cyst of the sole: comparison with traditional traditional epidermal cysts and trichilemmal cysts. *J cutan pathol*. 2005;32(4):280-85.
- [12] Harish S, Jan E, Ghert M, et al. Pseudotumoural appearance of a ruptured epidermal cyst in the foot. *Skeletal Radiol*. 2006;35(11):867-61.

PARTICULARS OF CONTRIBUTORS:

1. Senior Surgeon and Unit Chief, Department of General Surgery, St. Martha's Hospital, Bangalore, Karnataka, India.
2. Postgraduate Student, Department of General Surgery, St. Martha's Hospital, Bangalore, Karnataka, India.
3. Senior Surgeon, Department of General Surgery, St. Martha's Hospital, Bangalore, Karnataka, India.

NAME, ADDRESS, E-MAIL ID OF THE CORRESPONDING AUTHOR:

Dr. Sathyakrishna Basavapatna Ramakrishnaiah,
Senior Surgeon and Unit Chief, Department of General Surgery, St. Martha's Hospital, Bangalore--560086, Karnataka, India.
E-mail: dr.brsk@gmail.com

FINANCIAL OR OTHER COMPETING INTERESTS: None.

Date of Submission: Aug 02, 2016

Date of Peer Review: Aug 13, 2016

Date of Acceptance: Aug 29, 2016

Date of Publishing: Nov 01, 2016